

VALSALVA MANEUVER

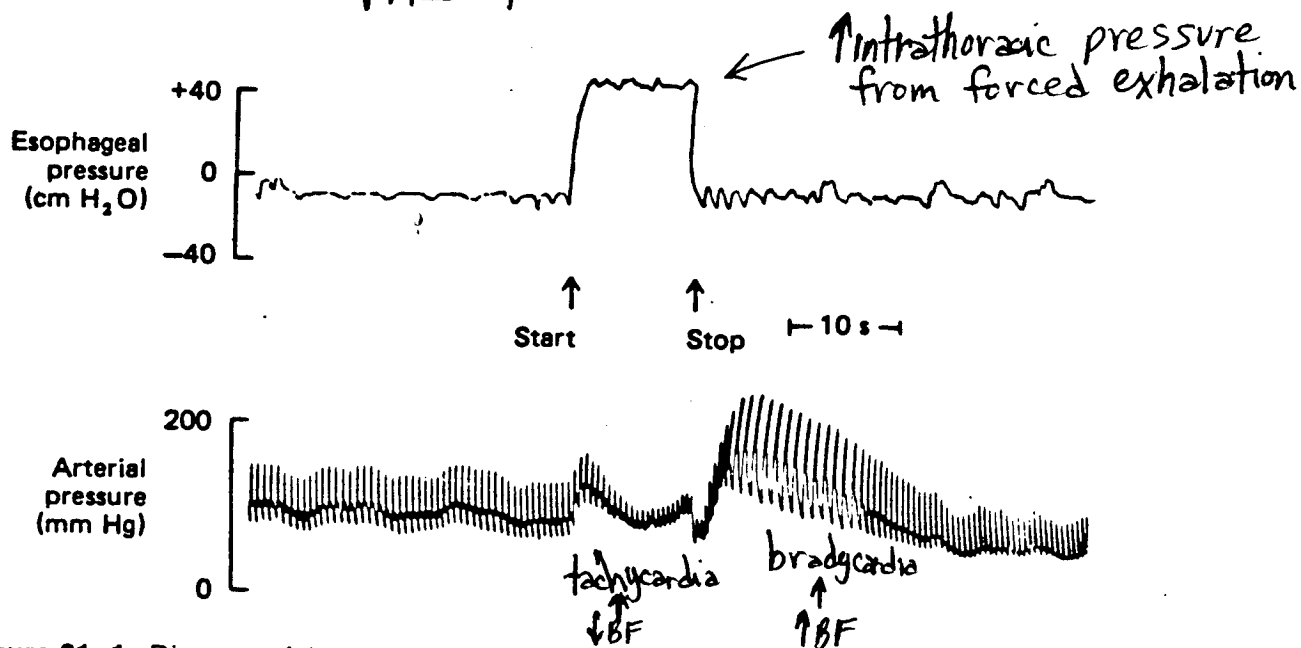


Figure 31-1. Diagram of the response to straining (the Valsalva maneuver) in a normal man, recorded with a needle in the brachial artery. (Courtesy of M McIlroy.)